



Managing Incidental Findings on Abdominal and Pelvic CT and MRI, Part 1: White Paper of the ACR Incidental Findings Committee II on Adnexal Findings

Maitray D. Patel, MD^a, Susan M. Ascher, MD^b,
Raj Mohan Paspulati, MD^c, Alampady K. Shanbhogue, MD^d,
Evan S. Siegelman, MD^e, Marjorie W. Stein, MD^f,
Lincoln L. Berland, MD^g

This white paper describes adnexal (ovarian and paraovarian) incidental findings found on CT and MRI in nonpregnant postmenarchal patients in whom no adnexal disorder is clinically known or suspected. This represents the first of 4 such papers from the ACR Incidental Findings Committee II, which used a consensus method based on repeated reviews and revisions and a collective review and interpretation of relevant literature. Recommendations for the management of incidental adnexal findings are organized into 4 main categories: benign-appearing cysts, probably benign cysts, adnexal masses with characteristic features, and all other adnexal masses, with pathways on the basis of patient menstrual status or age (when last menstrual period is unknown). A table and flowchart are provided for reference.

Key Words: Incidental findings, incidentaloma, ACR, consensus, CT, MRI, ovarian cyst

J Am Coll Radiol 2013;10:675-681. Copyright © 2013 American College of Radiology

FOREWORD

This white paper does not comprehensively review the interpretation and management of cystic and solid masses in the ovaries and paraovarian region but provides general guidance for managing common incidental find-

ings on CT and MRI, appreciating that individual care will vary depending on each patient's specific circumstances, the clinical environment, available resources, and the judgment of practitioners. Also, the term *guidelines* is not used in this or the prior white paper to avoid the implication that these represent components of the ACR Practice Guidelines and Technical Standards (which represent official ACR policy, having undergone a rigorous drafting and review process culminating in approval by the ACR Council) or the ACR Appropriateness Criteria[®] (which use a formal consensus-building approach using a modified Delphi technique). This white paper, which represents the collective experience of the members of the ACR Incidental Findings Committee II, was developed through a less formal process of repeated reviews and revisions of the draft document and does not represent official ACR policy. For these reasons, this white paper should not be used to establish the legal standard of care in any particular situation.

INTRODUCTION

Please refer to the accompanying overview [1] for a description of the purposes, structure, and process of the Incidental Findings Committee II, and the con-

The article is only available for CME credit online and CME credit may only be claimed online. Visit www.acr.org, ACR Education, online learning for more information.

^aDepartment of Radiology, Mayo Clinic Arizona, Phoenix, Arizona.

^bDepartment of Radiology, Georgetown University Hospital, Washington, District of Columbia.

^cDepartment of Radiology, University Hospitals, Case Western Reserve University, Cleveland, Ohio.

^dDepartment of Radiology, University of Texas Health Science Center at San Antonio, San Antonio, Texas.

^eDepartment of Radiology, Hospital of the University of Pennsylvania, Philadelphia, Pennsylvania.

^fDepartment of Radiology, Albert Einstein College of Medicine, Montefiore Medical Center, Bronx, New York.

^gDepartment of Radiology, University of Alabama at Birmingham, Birmingham, Alabama.

Corresponding author and reprints: Lincoln L. Berland, MD, University of Alabama at Birmingham, Department of Radiology, 619 S 19th Street, N454, Birmingham, AL 35249; e-mail: lberland@uabmc.edu.

ventions used in these 4 white papers, of which this is the first. The authors of this white paper represent the Adnexal Subcommittee membership, as listed in the appendix, and the roster of the entire Incidental Findings Committee II is listed in the appendix of the overview of this project [1].

INCIDENTAL ADNEXAL FINDINGS

This section addresses incidental findings on CT or MRI in nonpregnant postmenarchal patients in whom no adnexal disorder is clinically known or suspected. The recommendations below do not apply to patients with adnexal symptoms or positive pelvic physical examination findings. The recommendations also presume that the radiologist does not have access to prior relevant imaging or is unaware of the existence of prior relevant imaging that may have already evaluated the incidental finding; comparison with prior imaging may obviate the need for follow-up imaging or further imaging. These recommendations are summarized in the flowchart in Figure 1.

Optimally, imagers interpreting adnexal findings would have knowledge of the date of the patient's last menstrual period because the hormonal milieu influences the interpretation of findings. Although imaging facilities typically record menstrual information when performing pelvic sonograms, unfortunately, that practice is less common for CT and MRI studies that include the pelvis but that are not being performed for adnexal indications. When the patient's last menstrual period at the time of the CT or MRI examination is unknown, 50 years can be used as an arbitrary designation for the age of menopause [2], with a patient up to 50 years of age being premenopausal and a patient ≥ 50 years of age being postmenopausal. In this discussion, premenopause includes the perimenopausal phase, in which menstruation is commonly irregular or sporadic. Differences occur in the prevalence of incidental adnexal cysts in postmenopausal patients based on the number of years from the final menstrual period. The early postmenopausal period is defined as within 5 years of the final menstrual period or ages 50 to 55 years, when the last menstrual period is unknown [3]. Late postmenopause is >5 years from the final menstrual period or age >55 years, if the last menstrual period is unknown.

For this white paper, one category of incidental finding is the adnexal "benign-appearing cyst," which is defined as (1) an oval or round (2) unilocular mass of uniform fluid signal and attenuation, (3) with a regular or imperceptible wall, (4) without solid areas or mural nodules, and (5) <10 cm in maximum diameter. If the patient is premenopausal, the cyst can contain layering hemorrhage and still fall into the benign-appearing cyst category. Most commonly, a benign-appearing cyst is a non-neoplastic physiologic cyst, but it may be an endometrioma, a paraovarian or paratubal cyst, an atypical

round or oval-shaped hydrosalpinx, or an ovarian cystadenoma or cystadenofibroma. Although there are other cystic adnexal collections that are benign, including tubular-shaped hydrosalpinges, angular-shaped peritoneal inclusion cysts, multiloculated endometriomas, and septated cystadenomas or cystadenofibromas, these do not meet the definition of benign-appearing cyst. Another category of incidental findings is the "probably benign cyst"; as used in this white paper, the term refers to an adnexal cyst that would have met the criteria for a benign-appearing cyst but does not because of one or more of the following observations: (1) it has angulated margins, (2) it is not round or oval in shape, (3) a portion of the cyst is poorly imaged (eg, a portion of the cyst might be obscured by metal streak artifact from hip prosthesis on CT of the pelvis), or (4) the image has reduced signal-to-noise ratio, usually because of technical parameters or in some cases because the study was performed without intravenous contrast.

It is important for those interpreting CT and MR studies performed on women to be familiar with normal adnexal findings. On intravenous contrast-enhanced CT studies, the ovary often enhances less than the myometrium [4], and if normal sized, this ovarian hypoattenuation should not be described as an abnormal finding. The range of normal ovarian size varies as a function of hormonal status; in premenopausal patients, ovaries up to 20 cm³ in volume are within the upper 95% confidence interval for normal, whereas in postmenopausal women, the upper 95% confidence interval for normal volume is 10 cm³ [5]. For an oval-shaped structure, these volume limits generally translate to a maximum linear dimension of 5 cm for premenopausal women and 3 to 4 cm for postmenopausal women, with the size of the ovary normally decreasing progressively after 30 years of age [5].

Unless suppressed by hormonal agents or absent because of ovarian failure, follicles are usually present in the normal ovaries of premenopausal women. Some have suggested that follicles should not be described as cysts, so that they are not confused for abnormal cystic masses [6], but these follicles are essentially small fluid-filled "simple" cysts that enlarge during the follicular phase of the menstrual cycle, with one follicle usually becoming dominant and releasing an egg at ovulation. The follicle that releases the egg becomes the corpus luteum, which typically collapses because of the expulsion of the fluid previously in the dominant follicle into the peritoneum at the time of ovulation. The collapsed corpus luteum can have a characteristic appearance on contrast-enhanced CT [7]. However, if the wall seals, the corpus luteum can form a cyst larger than the dominant follicle from which it arose. That cyst may be simple or hemorrhagic, often with a peripheral rim of hypervascularity, readily demonstrable with Doppler and contrast-enhanced CT. This has been called the "hyperenhancing

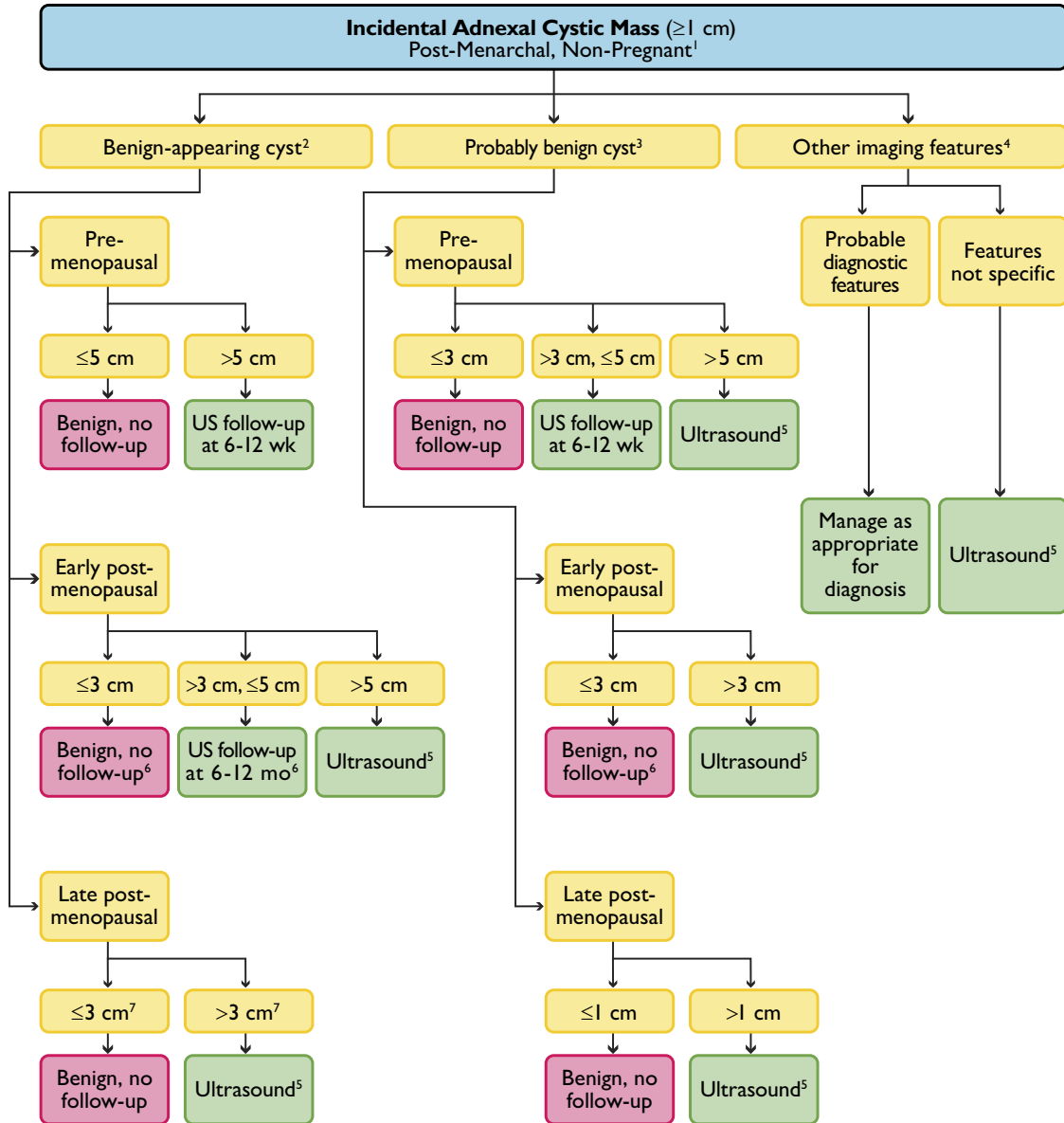


Fig 1. Incidental adnexal cystic mass flowchart. ¹Exclusions: (a) normal findings, including hypodense ovary, crenulated enhancing wall of corpus luteum, asymmetric ovary (within 95% confidence interval for size) with normal shape; (b) unimportant findings, including calcifications without associated noncalcified mass; (c) previous characterization with ultrasound or MRI; and (d) documented stability in size and appearance for >2 years. ²Should have all of the following features: (a) oval or round; (b) unilocular, with uniform fluid attenuation or signal (layering hemorrhage acceptable if premenopausal); (c) regular or imperceptible wall; (d) no solid area, mural nodule; and (e) <10 cm in maximum diameter. ³Refers to an adnexal cyst that would otherwise meet the criteria for a benign-appearing cyst except for one or more of the following specific observations: (a) angulated margins, (b) not round or oval in shape, (c) a portion of the cyst is poorly imaged (eg, a portion of the cyst may be obscured by metal streak artifact on CT of the pelvis), and (d) the image has reduced signal-to-noise ratio, usually because of technical parameters or in some cases because the study was performed without intravenous contrast. ⁴Features of masses in this category include (a) solid component, (b) mural nodule, (c) septations, (d) higher than fluid attenuation, and (e) layering hemorrhage if postmenopausal. ⁵This indicates that ultrasound should be performed promptly for further evaluation, rather than in follow-up. ⁶A benign-appearing cyst ≤5 cm with suspected internal hemorrhage in a patient aged ≤55 years, or within 5 years of menopause, should be followed in 6 to 12 weeks because hemorrhagic cysts in early postmenopause are possible, although rare. ⁷May decrease threshold from 3 cm to lower values down to 1 cm to increase sensitivity for neoplasm.

rim sign” on CT [8]. Internal hemorrhage into a non-neoplastic cyst may be recognized on CT by the presence of layering hyperdense material [4].

Incidental adnexal cysts discovered by imaging are common; when follicles are counted as cysts, they are practically ubiquitous in premenopausal women. They

are also routinely identified in postmenopausal women. One study involving 15,000 postmenopausal women demonstrated that 18% had developed unilocular cysts <10 cm, with 69% resolving spontaneously [9]. There is ample evidence that simple cysts in women of any age (including those in late postmenopause) up to 10 cm in diameter are rarely malignant and when malignant are most often borderline malignancies, are >5 cm in diameter, and have wall nodules on follow-up sonographic imaging [9]. In some cases, these wall nodules are small, so they may have been overlooked at initial evaluation. Therefore, the cyst may not truly have been “simple” at presentation. There has not been adequate research to determine how often categorizing an adnexal cyst as “simple” on CT or MRI (either with or without contrast enhancement) correlates with the same categorization by ultrasound. Nevertheless, the committee recommends applying the available evidence on the natural history of sonographically identified simple cysts to cysts that meet criteria for designation as a benign-appearing or probably benign on CT or MR, and modifying recommendations on the basis of menopausal status and size, as is done with ultrasound.

Adnexal Cysts in Premenopausal Women

Recognizing the normal physiologic sequence in premenopausal women and the resulting sonographic findings, a consensus panel formed by the Society of Radiologists in Ultrasound (SRU) in 2009 concluded that simple cysts ≤ 3 cm in maximum size, incidentally identified sonographically in premenopausal women, can be interpreted as normal, not even requiring mention in an ultrasound report [10]. Simple cysts in premenopausal women >3 cm but ≤ 5 cm in maximum diameter can be interpreted as almost certainly normal and should not lead to a recommendation for imaging follow-up [10]. Furthermore, that panel also concluded that a confidently characterized hemorrhagic ovarian cyst ≤ 5 cm in size identified incidentally in a premenopausal woman should not have a recommendation for imaging follow-up [10]. The committee recommends a modified version of the SRU approach for incidentally identified adnexal findings found on CT or MRI in premenopausal women, as detailed below.

In a premenopausal woman, because non-neoplastic physiologic cysts are so common, when a benign-appearing cyst or a probably benign cyst measuring ≤ 3 cm in maximum size is identified on CT or MRI, it should be considered normal. When an adnexal cyst identified on CT or MRI in a premenopausal woman is >3 cm in size, it is of sufficient size to be well characterized, so it should be readily apparent whether the cyst falls into the benign-appearing cyst category or the probably benign cyst category; the size threshold at which further imaging is recommended differs on the basis of which categorization fits best. If the imager is reasonably confident that the mass is a benign-appearing cyst and the cyst is incidental and asymptomatic, it does not need further

prompt or repeat imaging or follow-up if ≤ 5 cm in maximum diameter. On the other hand, if the cyst in the premenopausal woman meets criteria to designate it as a probably benign cyst but does not meet the more stringent criteria to designate it as a benign-appearing cyst, the size threshold at which the cyst does not need further prompt or repeat imaging or follow-up is 3 cm.

The ability to identify small mural nodules on CT or unenhanced MRI in borderline or frank malignancies that otherwise appear benign has not been firmly established. As a result, in premenopausal women, the committee recommends short interval follow-up ultrasound evaluation in 6 to 12 weeks for benign-appearing adnexal cysts >5 cm in diameter and probably benign adnexal cysts >3 cm in diameter. Follow-up ultrasound in 6 to 12 weeks, rather than prompt further evaluation, is preferable in a premenopausal woman because the cyst may resolve or decrease in size on follow-up, thus concluding the diagnostic evaluation with only one additional imaging test. If the cyst persists, the 6- to 12-week follow-up will help further evaluate the cyst for mural nodules that some borderline malignancies contain and serve as a baseline for further sonographic follow-up. If additional periodic evaluation is needed because the cyst remains present on follow-up sonography, further follow-up recommendations should be based on the sonographic appearance using the SRU approach.

Adnexal Cysts in Postmenopausal Women (Early vs Late)

In postmenopausal women, a similar approach is recommended using different size thresholds, somewhat modified by whether the patient is in the early postmenopausal period or late postmenopausal period. It is increasingly well recognized that simple cysts are common in postmenopausal patients, especially for those in early postmenopause but also in late postmenopause [11]. One study showed that 21% of patients in late postmenopause had simple cysts up to 1 cm in diameter on sonographic evaluation [12]. A study analyzing the natural history of sonographically characterized unilocular cysts in postmenopausal women showed that those <5 cm in size have a minimal chance of being malignant, with most of these benign postmenopausal cysts being <3 cm in size [9]. These nonmalignant simple cysts may be arrested follicles, other non-neoplastic cysts including paraovarian or paratubal cysts, or benign neoplasms such as cystadenomas or cystadenofibromas.

On the basis of these data and other studies, the SRU consensus panel concluded that it would be reasonable not to recommend further imaging of incidental simple cysts identified sonographically in postmenopausal women when ≤ 1 to 3 cm in size. The exact cutoff used in any given practice may be chosen on the basis of how strongly the practice wanted to minimize the very small risk for missing an asymptomatic benign neoplasm that might grow and later prove symptomatic. Although the exact size threshold between 1 and 3 cm for pursuing

follow-up was debated among the panelists, all advocated that cysts ≤ 1 cm should not be followed.

Similarly, the committee recommends that an adnexal cyst identified on CT or MRI measuring ≤ 1 cm in maximum size in any phase of the postmenopausal period should be considered benign unless there are clearly identified imaging findings suspicious for malignancy or evidence of possible metastatic ovarian cancer. The imager does not need to be convinced that all benign features of a cyst are demonstrated because this can be difficult to confirm for subcentimeter lesions, especially without intravenous contrast or in the presence of some common artifacts. However, no suspicious imaging features should be present.

In early postmenopause, the committee does not recommend prompt or follow-up ultrasound for a benign-appearing cyst measuring ≤ 3 cm in maximum size. Because the relative prevalence of non-neoplastic cysts decreases compared with benign neoplasms as cyst size increases, if the benign-appearing cyst in the early postmenopausal woman is >3 but ≤ 5 cm, follow-up sonographic imaging is recommended to monitor the growth of the incidental lesion. Benign neoplasms typically slowly increase in size, whereas non-neoplastic cysts typically resolve or remain stable in size. When non-neoplastic cysts resolve in postmenopausal patients, they do so over months, not the shorter interval of resolution found in premenopausal women [11]. Therefore, the committee recommends that the first follow-up ultrasound study for a benign-appearing cyst of 3 to 5 cm in diameter found in a woman in early postmenopause be performed in 6 to 12 months, with further evaluation of the lesion on the basis of the sonographic appearance at that time. When an incidentally identified benign-appearing cyst in a woman in early postmenopause is >5 cm in size, the committee recommends prompt sonographic evaluation to ensure that small wall nodules have not been overlooked.

In late postmenopause, the committee does not recommend prompt or follow-up ultrasound of an asymptomatic benign-appearing cyst ≤ 3 cm in maximum diameter. Again, because the relative prevalence of non-neoplastic cysts decreases compared with benign neoplasms as women get older and cyst size increases, the interpreting physician may reasonably choose to decrease the size threshold for pursuing prompt sonographic imaging or follow-up sonographic imaging in a late postmenopausal woman. For example, one might choose to pursue prompt or follow-up sonographic imaging for cysts <3 cm in size depending on patient age or imaging technical factors influencing the imager's assessment confidence (eg, CT radiation dose, amount of streak artifact). In a late postmenopausal patient, the committee recommends that an incidentally detected benign-appearing cyst on CT or MRI that is >3 cm in diameter undergo further evaluation. To facilitate effective comparison between examinations over time, it is prudent to perform prompt imaging with ultrasound to establish a

baseline appearance and to further characterize the internal architecture of the lesion.

For probably benign cysts, size thresholds for pursuing prompt follow-up ultrasound in postmenopausal patients differ depending on whether patients are in early or late postmenopause. When a patient is in early postmenopause, the committee recommends that a probably benign cyst undergo prompt follow-up ultrasound if >3 cm in maximum diameter. When a patient is in late postmenopause, the committee recommends that a probably-benign cyst be further evaluated with prompt ultrasound if >1 cm in maximum diameter.

Adnexal Cystic Masses With Characteristic CT or MRI Findings

CT, and to a larger extent MRI, can show imaging features of adnexal masses that are characteristic or highly suggestive for particular diagnostic entities, such as paraovarian cyst, hydrosalpinx, peritoneal inclusion cyst, cystic teratoma, endometrioma, exophytic leiomyoma, ovarian fibroma, and ovarian carcinoma [13-21]. A description of the diagnostic criteria that enable confident CT and MRI diagnosis of these entities is not completely reviewed here but is highlighted in Table 1. When a reasonably confident diagnosis of a particular adnexal entity is made incidentally on CT or MRI, further management should be based on the features of the mass and on clinical factors. Although an oversimplification, most non-neoplastic incidental findings in both premenopausal and postmenopausal women (specifically referring to ovarian non-neoplastic cysts, paraovarian cysts, hydrosalpinges, and peritoneal inclusion cysts) do not need further evaluation. The exception in this category is endometrioma because there is a known small risk for the development of clear cell carcinoma in endometriomas [22-24]. Thus, even asymptomatic incidental endometriomas merit follow-up, although the size threshold for initiating this follow-up and the optimal frequency of periodic follow-up imaging have not been scientifically established. Current SRU recommendations on the basis of limited scientific evidence suggest initial follow-up at yearly intervals, with no consensus on extended follow-up strategies [10]. Because of cost considerations, the incidentally identified endometrioma on MRI is best followed using ultrasound, unless it cannot be satisfactorily imaged sonographically.

The clinical management of incidentally identified benign ovarian neoplasms that are confidently characterized on CT or MRI, which would include some cystic teratomas and ovarian fibromas, will depend on patient age and comorbidities. Although cystic teratomas are known to enlarge slowly, surgeons typically remove dermoids in younger patients because they have a long-term potential for progressive growth and ovarian torsion. If not surgically removed, periodic follow-up of cystic teratomas is recommended on the basis of the 1% risk for malignant

Table 1. Adnexal CT and MR findings enabling specific diagnosis with a high degree of certainty

Entity	CT Findings	MR Findings	References
Paraovarian cyst	Thin-walled adnexal cyst with separate adjacent normal appearing ovary	Same as CT	[13]
Hydrosalpinx	Tubular shape, waist sign, incomplete septations, separate ovary	Same as CT	[14]
Peritoneal inclusion cyst	Angular margins of pelvic fluid collection, spider-web pattern (septated fluid around central ovary), appropriate clinical history	Same as CT	[15]
Cystic teratoma	Ovarian mass containing fat, tooth	Ovarian mass containing lipid and/or fat; calcium better detected on CT	[16]
Endometrioma	No specific features	Hyperintense T1 signal intensity, T2 shading, multiplicity, other findings of endometriosis	[17]
Leiomyoma	Characteristic calcifications, uterine origin	Low T2 signal intensity, beak of uterine tissue around portion of the mass, bridging vessels between mass and uterus, separate ovary, enhance more than ovarian fibromas	[18,19]
Ovarian fibroma	No specific features	Low T2 signal in well-circumscribed mass in ovary, enhancement less than myometrium; larger lesions can have heterogeneous high T2 signal and heterogeneous enhancement	[20]
Malignancy	Enhancing mural nodules, thick septa, ascites, peritoneal implants, para-aortic adenopathy	Same as CT	[21]

transformation, recognizing that series describing this transformation have shown that malignant cystic teratomas are uniformly very large [25-27]. No such transformative risk has been ascribed to ovarian fibromas, so these incidental masses, if confidently diagnosed on MRI, may not require further follow-up imaging.

Ovarian cancer and metastatic disease involving the ovaries can occasionally be incidentally detected by CT or MRI because symptoms can be vague or nonexistent, with masses clinically unsuspected. When CT or MRI findings imply adnexal cancer, surgical evaluation is usually indicated. Prompt further imaging with ultrasound is not necessary when the CT or MRI findings are compelling. Although surgical staging is the current standard of care, a dedicated imaging study with protocol tailored for staging might be beneficial [28].

All Other Adnexal Masses

For an adnexal incidental finding that is not covered by the discussion above or the flowchart, and not addressed the other white papers in this series, such as lymph nodes and vascular structures, prompt sonographic imaging is recommended when there is suspicion of a mass. The differential diagnosis for any particular mass or finding will vary on the basis of the specific imaging features present, and ultrasound can be used to try to detect features that would enable a confident diagnosis or management strategy. It is important to note that the recommendation for further imaging is predicated on the suspicion of the presence of a mass; when the incidental adnexal finding is cal-

cification without an associated noncalcified mass, sonographic imaging will not be useful, and the finding should be considered benign.

TAKE-HOME POINTS

- In a premenopausal woman, when a benign-appearing cyst or a probably benign cyst measures ≤ 3 cm, it should be considered normal.
- In premenopausal women, the committee recommends follow-up ultrasound in 6 to 12 weeks for benign-appearing adnexal cysts >5 cm in diameter and probably benign adnexal cysts >3 cm in diameter.
- The committee recommends that the first follow-up ultrasound study for a benign-appearing cyst of 3 to 5 cm in diameter found in a woman in early postmenopause be performed in 6 to 12 months.
- When an incidentally identified benign-appearing cyst in a woman in early postmenopause is >5 cm in size, the committee recommends prompt sonographic evaluation to ensure that small wall nodules have not been overlooked.
- In late postmenopause, the committee does not recommend prompt or follow-up ultrasound of an asymptomatic benign-appearing cyst ≤ 3 cm in maximum diameter.
- In early postmenopause, the committee recommends prompt ultrasound for a probably benign cyst >3 cm and, in late postmenopause, for a probably benign cyst >1 cm in maximum diameter.

ACKNOWLEDGMENTS

The authors thank David Kurth of the ACR staff, who helped support and coordinate the activities that led to this report, and Drs Deborah Levine, Joel Platt, Marcia Javitt, and Mark Baker for review and suggestions.

APPENDIX

Committee Members

Incidental Findings Committee II: Lincoln L. Berland, MD (chair).

Ovarian/Paraovarian Subcommittee: Maitray D. Patel, MD (chair), Susan M. Ascher, MD, Raj Mohan Paspulati, MD, Alampady K. Shanbhogue, MD, Evan S. Siegelman, MD, Marjorie W. Stein, MD.

Ex Officio: James A. Brink, MD (chair), ACR Body Imaging Commission.

REFERENCES

- Berland LL. Overview of white papers of the ACR Incidental Findings Committee II on ovarian and paraovarian, vascular, splenic, nodal, gallbladder, and biliary findings. *J Am Coll Radiol* 2013;10:672-4.
- Im SS, Gordon AN, Buttin BM, et al. Validation of referral guidelines for women with pelvic masses. *Obstet Gynecol* 2005;105:35-41.
- Soules MR, Sherman S, Parrott E, et al. Executive summary: Stages of Reproductive Aging Workshop (STRAW). *Fertil Steril* 2001;76:874-8.
- Patel MD, Dubinsky TJ. Reimaging the female pelvis with ultrasound after CT: general principles. *Ultrasound Q* 2007;23:177-87.
- Pavlik EJ, DePriest PD, Gallion HH, et al. Ovarian volume related to age. *Gynecol Oncol* 2000;77:410-2.
- Timor-Tritsch IE, Goldstein SR. The complexity of a "complex mass" and the simplicity of a "simple cyst." *J Ultrasound Med* 2005;24:255-8.
- Borders RJ, Breiman RS, Yeh BM, Qayyum A, Coakley FV. Computed tomography of corpus luteal cysts. *J Comput Assist Tomogr* 2004;28:340-2.
- Shin YM, Lee JK, Turan N, Mauro D, Chong W. Computed tomography appearance of ovarian cysts with hyperenhancing rim during the menstrual cycle in women of different ages. *J Comput Assist Tomogr* 2010;34:532-6.
- Modesitt SC, Pavlik EJ, Ueland FR, DePriest PD, Kryscio RJ, van Nagell JR Jr. Risk of malignancy in unilocular ovarian cystic tumors less than 10 centimeters in diameter. *Obstet Gynecol* 2003;102:594-9.
- Levine D, Brown DL, Andreotti RF, et al. Management of asymptomatic ovarian and other adnexal cysts imaged at US: Society of Radiologists in Ultrasound consensus conference statement. *Radiology* 2010;256:943-54.
- Castillo G, Alcazar JL, Jurado M. Natural history of sonographically detected simple unilocular adnexal cysts in asymptomatic postmenopausal women. *Gynecol Oncol* 2004;92:965-9.
- Healy DL, Bell R, Robertson DM, et al. Ovarian status in healthy postmenopausal women. *Menopause* 2008;15:1109-14.
- Kishimoto K, Ito K, Awaya H, Matsunaga N, Outwater EK, Siegelman ES. Paraovarian cyst: MR imaging features. *Abdom Imaging* 2002;27:685-9.
- Kim MY, Rha SE, Oh SN, et al. MR imaging findings of hydrosalpinx: a comprehensive review. *Radiographics* 2009;29:495-507.
- Jain KA. Imaging of peritoneal inclusion cysts. *AJR Am J Roentgenol* 2000;174:1559-63.
- Outwater EK, Siegelman ES, Hunt JL. Ovarian teratomas: tumor types and imaging characteristics. *Radiographics* 2001;21:475-90.
- Gougoutas CA, Siegelman ES, Hunt J, Outwater EK. Pelvic endometriosis: various manifestations and MR imaging findings. *AJR Am J Roentgenol* 2000;175:353-8.
- Weinreb JC, Barkoff ND, Megibow A, Demopoulos R. The value of MR imaging in distinguishing leiomyomas from other solid pelvic masses when sonography is indeterminate. *AJR Am J Roentgenol* 1990;154:295-9.
- Kim JC, Kim SS, Park JY. "Bridging vascular sign" in the MR diagnosis of exophytic uterine leiomyoma. *J Comput Assist Tomogr* 2000;24:57-60.
- Shinagare AB, Meylaerts LJ, Laury AR, Mortelet KJ. MRI features of ovarian fibroma and fibrothecoma with histopathologic correlation. *AJR Am J Roentgenol* 2012;198:W296-303.
- Iyer VR, Lee SI. MRI, CT, and PET/CT for ovarian cancer detection and adnexal lesion characterization. *AJR Am J Roentgenol* 2010;194:311-21.
- Kawaguchi R, Tsuji Y, Haruta S, et al. Clinicopathologic features of ovarian cancer in patients with ovarian endometrioma. *J Obstet Gynaecol Res* 2008;34:872-7.
- Kobayashi H, Sumimoto K, Kitanaka T, et al. Ovarian endometrioma—risk factors of ovarian cancer development. *Eur J Obstet Gynecol Reprod Biol* 2008;138:187-93.
- Kobayashi H, Sumimoto K, Moniwa N, et al. Risk of developing ovarian cancer among women with ovarian endometrioma: a cohort study in Shizuoka, Japan. *Int J Gynecol Cancer* 2007;17:37-43.
- Park JY, Kim DY, Kim JH, Kim YM, Kim YT, Nam JH. Malignant transformation of mature cystic teratoma of the ovary: experience at a single institution. *Eur J Obstet Gynecol Reprod Biol* 2008;141:173-8.
- Rim SY, Kim SM, Choi HS. Malignant transformation of ovarian mature cystic teratoma. *Int J Gynecol Cancer* 2006;16:140-4.
- Yamanaka Y, Tateiwa Y, Miyamoto H, et al. Preoperative diagnosis of malignant transformation in mature cystic teratoma of the ovary. *Eur J Gynaecol Oncol* 2005;26:391-2.
- Shaaban A, Rezvani M. Ovarian cancer: detection and radiologic staging. *Clin Obstet Gynecol* 2009;52:73-93.



CME: This article is only available for CME credit online and CME credit may only be claimed online. Visit www.acr.org, ACR Education, online learning for more information.